

# Oropharynx Detection in PET-CT for Tumor Segmentation

Vincent Andrearczyk<sup>1</sup>, Valentin Oreiller<sup>1,2</sup>, and Adrien Depoursingé<sup>1,2</sup>

<sup>1</sup>*Institute of Information Systems, University of Applied Sciences Western Switzerland (HES-SO), Sierre, Switzerland*

<sup>2</sup>*Centre Hospitalier Universitaire Vaudois (CHUV), Lausanne, Switzerland*

## Abstract

We propose an automatic detection of the oropharyngeal area in PET-CT images. This detection can be used to preprocess images for efficient segmentation of Head and Neck (H&N) tumors in the cropped regions by a Convolutional Neural Network (CNN) for treatment planning and large-scale radiomics studies (e.g. prognosis prediction). The developed method is based on simple image processing steps to segment the brain on the PET image and retrieve a fixed size bounding box of the extended oropharyngeal region. We evaluate the results by measuring whether the primary Gross Tumor Volume (GTV) is fully contained in the bounding box. 194 out of 201 regions (96.5%) are correctly detected. The code is available on our GitHub repository.<sup>1</sup>

**Keywords:** Medical imaging, oropharynx, detection, preprocessing

## 1 Introduction

Head and Neck (H&N) cancers are among the most common cancers worldwide (5<sup>th</sup> leading cancer by incidence) [Parkin et al., 2005]. In particular, the oropharynx is located in the middle part of the throat (pharynx) and is a common site for the development of H&N tumors.

In [Andrearczyk et al., 2020], we developed an automatic H&N primary tumor and lymph nodes segmentation from Positron Emission Tomography-Computed Tomography (PET-CT) images using a V-Net Convolutional Neural Network (CNN). To analyze the oropharyngeal region, a bounding box was used to crop the input volume to input to the CNN. This bounding box was defined by centering a fixed size volume around a minimal bounding box containing the tumor. While this approach allowed us to evaluate the CNN performance, an automatic region detection is necessary in clinical practice to obtain a fully automatic pipeline. To this end, we propose a simple method based on morphological operations in the PET image to automatically locate the extended oropharyngeal region with a bounding box. To evaluate the approach in Section 3, we consider a detection to be correct if the primary tumor is fully contained within the bounding box.

## 2 Methods

In this section, we describe the automatic detection of a  $144 \times 144 \times 144^2$  bounding box representing the extended oropharyngeal region.

The region detection is based on brain detection in the PET volume. We first apply a Gaussian filter with a standard deviation  $\sigma = 3$  to remove potential noise and high frequencies that could impair the following

---

<sup>1</sup>[github.com/voreille/hector](https://github.com/voreille/hector), as of August 2020.

<sup>2</sup>This size is in  $\text{mm}^3$ . It is used because it covers the oropharyngeal region and is a typical input size for standards 3D CNNs that will be used with these data. Naturally, the results presented in Section 3 depend on this size since a larger bounding box would more likely contain the tumor.

threshold. A threshold is then applied to the Standardized Uptake Values (SUV) in the PET image. A fixed threshold value of three is used as it allows a good separation of the brain and the rest of the head. We then simply find the brain as the largest connected component. Note that we compute this detection only in the top third (z-axis) of the PET volume because high SUV values can be found in the bladder and in the injection point for some cases.

Once the brain is segmented, we define the extended oropharyngeal region as a bounding box with a fixed physical size ( $144 \times 144 \times 144$ ) using predefined shifts from the brain volume. In the following description, we consider the axes in the patient reference; i.e. x goes from right to left, y from anterior to posterior and z from inferior to superior. On the z-axis, we find the lowest voxel of the brain and set the center of the box three centimeters below. On the x-axis, the center is set as the midpoint between the most-left and most-right brain voxels. Finally, on the y-axis, the center is set as the midpoint between the most-anterior and most-posterior brain voxels, shifted by three centimeters forward. The shift values are manually set based on a rough visual approximation of the head dimensions and (distances between brain and throat, mouth, tumor) and tilt. Although head sizes and poses vary, the algorithm is robust to these variations and to variations in the shift values since the bounding boxes are larger than the oropharyngeal region. Alternatively, these shift values could be computed from a training set if ground truth annotations of the oropharyngeal regions were available. The code for this automatic detection is available on our github repository<sup>3</sup>.

### 3 Results and Discussions

We evaluate the proposed method on the 201 training cases used in the HEad and neCK TumOR (HECKTOR) tumor segmentation challenge at MICCAI 2020<sup>4</sup>. Examples of bounding boxes overlaid on top of 2D slices of the original volumes are illustrated in Fig. 1 together with the brain segmentations. A total of 194 out of 201 regions (96.5%) are correctly detected by our method, i.e. the primary tumors are fully contained within the bounding boxes. The failure cases, i.e. primary tumor not fully contained in the bounding box or entirely missed, are illustrated in Fig. 2 and detailed in the following. Four misdetections are due to abnormal SUV values in the PET image (e.g Fig. 2.a). These can be due to incorrect information such as patient weight or time between injection and acquisition. To prepare the challenge data, we simply correct the threshold value for these cases to detect correct bounding boxes. For the training of segmentation algorithms after our region detection, the SUVs can be standardized as in [Mortazi et al., 2020] to account for these possibly incorrect SUV values. The other misdetections are due to the brain being outside the image for one (see Fig. 2.b) and a high tumor on the z-axis together with the head tilted (e.g. Fig. 2.c) for the other two.

### 4 Conclusions and Future Work

In this short paper, we showed that simple image processing techniques can be used to accurately detect the extended oropharyngeal region containing primary H&N tumors. The automatic detection was successful for 96.5% of the cases, while the failure instances were due to extreme cases (see Fig. 2) and were easily corrected. Another approach could be considered by registering the CT volumes to a reference volume with known anatomical regions. However, it is a difficult task due to the variation in body parts that are covered by the different scans (e.g. full body, head only or cropped brain).

This method was used to pre-define bounding boxes for an automatic tumor segmentation task in the development of the HECKTOR challenge at MICCAI 2020 which will allow participants to evaluate and compare their segmentation algorithms in PET-CT images. In turn, it will provide a fully automatic pipeline including region detection and tumor segmentation with high potential in clinical practice as well as radiomics studies [Zwanenburg et al., 2020].

---

<sup>3</sup>[github.com/voreille/hecktor](https://github.com/voreille/hecktor), as of August 2020.

<sup>4</sup><https://www.aicrowd.com/challenges/hecktor>, as of July 2020.

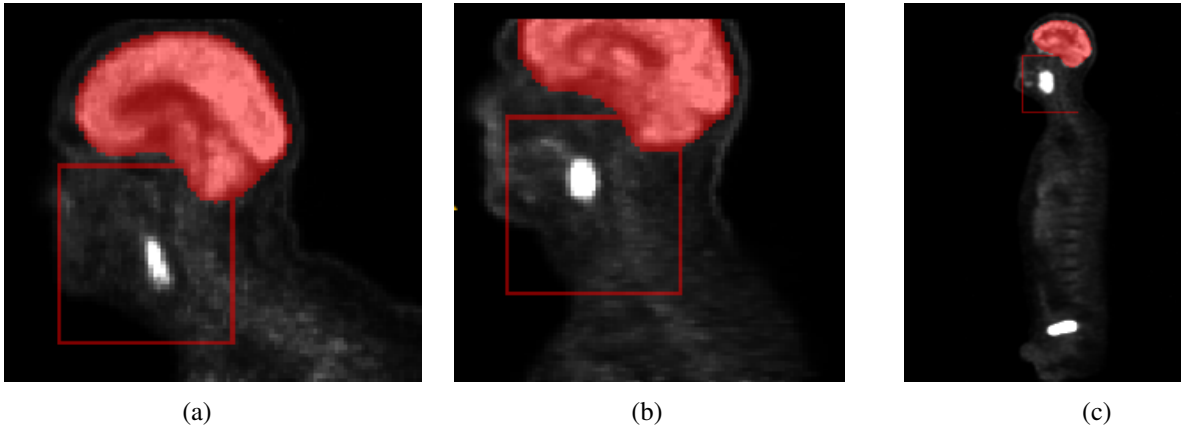


Figure 1: Examples of 2D slices of automatically generated bounding boxes of the extended oropharyngeal region. We illustrate the bounding box and the brain segmentation overlaid on top of the PET image. The primary gross tumor volume is characterized by a high PET activation.

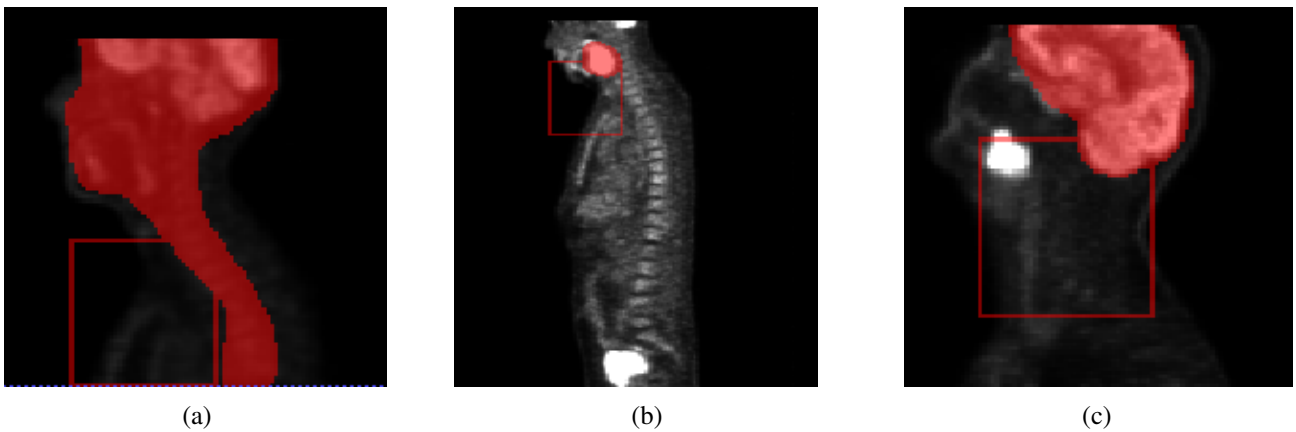


Figure 2: Examples of 2D slices of failed extended oropharyngeal region detection. (a) The SUVs are low due to erroneous information in the DICOM metadata resulting in an incorrect segmentation of the brain, thus of the oropharynx, (b) The brain is outside the image resulting in a wrong segmentation and (c) The head is tilted and the tumor is high on the z-axis, resulting in a bounding box too low.

## Acknowledgments

This work was supported by the Swiss National Science Foundation (SNSF, grant 205320\_179069) and the Swiss Personalized Health Network (SPHN via the IMAGINE and QA4IQI projects).

## References

- [Andrearczyk et al., 2020] Andrearczyk, V., Oreiller, V., Vallières, M., Castelli, J., Elhalawani, H., Boughdad, S., Jreige, M., Prior, J. O., and Depeursinge, A. (2020). Automatic segmentation of head and neck tumors and nodal metastases in PET-CT scans. In *Medical Imaging with Deep Learning (MIDL 2020)*.
- [Mortazi et al., 2020] Mortazi, A., Udupa, J. K., Tong, Y., and Torigian, D. A. (2020). A post-acquisition standardization method for positron emission tomography images. In *Medical Imaging 2020: Computer-Aided Diagnosis*, volume 11314, page 113143U. International Society for Optics and Photonics.
- [Parkin et al., 2005] Parkin, D. M., Bray, F., Ferlay, J., and Pisani, P. (2005). Global cancer statistics, 2002. *CA: a cancer journal for clinicians*, 55(2):74–108.
- [Zwanenburg et al., 2020] Zwanenburg, A., Vallières, M., Abdalah, M. A., Aerts, H. J., Andrearczyk, V., Apte, A., Ashrafinia, S., Bakas, S., Beukinga, R. J., Boellaard, R., et al. (2020). The image biomarker standardization initiative: standardized quantitative radiomics for high throughput image-based phenotyping. *Radiology*.